International Journal of Pharma Sciences
Vol. 6, No. 5 (2016): 1658-1668
Research Article
Open Access

ISSN: 2320-6810

Gastroprotective and Antioxidant Activities of Rutin against Ethanol-induced Gastric Mucosal Erosion in Rats via suppression of Inflammation, Oxidative Stress and Apoptosis in Stomach tissues

Samy Ali Hussein[1,*], Mohamed M. Karousa[2], Aziza Amin[3] and Maher A. Awadalla A[1]

[1] *Department of Biochemistry, Faculty of Vet. Med. Moshtohor, Benha University, Egypt.*
[2] *Department of Animal Hygiene, Behavior and management, Faculty of Vet. Med. Moshtohor, Benha University, Egypt.*
[3] *Department of pathology, Faculty of Vet. Med. Moshtohor, Benha University, Egypt.*

* Corresponding author: Samy Ali Hussein, e-mail: Samyaziza@yahoo.com

Received: 24 July 2016 Accepted: 18 August 2016 Online: 01 September 2016

ABSTRACT

The potential protective and beneficial effect of rutin (RTN) against ethanol-induced gastric mucosal erosion (gastritis) in rats was evaluated. Fourty male albino rats were divided into four groups. Control group received no drugs, gastritis group administered with a single oral dose of 1 ml/rat of absolute ethanol, gastritis + RTN protected group received RTN (200 mg/kg body weight/day) orally for 14 days prior ethanol administration and gastritis + RTN treated group received RTN and the treatment was continued for 7 days later. Blood samples and gastric tissue were collected for determination of some serum and gastric tissues parameters and histopathological examination. The obtained results showed a significant decrease in serum nitric oxide (NO), sialic acid (SA), and gastric tissue GSH, vitamin C concentrations and GPX, SOD, GR and CAT activities in gastritis induced rats. However, myeloperoxidase (MPO) and cyclooxygenase II (COX-2) activities, nuclear factor kappa B p65(NF-KB p65), tumor necrosis factor-alpha (TNF-α), interleukin-6 (IL-6), interleukin-1beta (IL-1β), L- Malondialdehyde (L-MDA) and DNA-fragmentation were significantly increased. Administration of RTN was capable to alleviate gastritis induced by ethanol through increasing of NO, SA, GSH, vitamin C concentrations, GPx, SOD, GR, CAT activities in addition to reducing NF-KB p65, TNF-α, IL-6, IL-1β, L-MDA, DNA-fragmentation concentrations and MPO, COX-2 activities. Additionally, several pathological variations were verified in gastric tissues of rats in group II. Remarkably, the severity of these alterations was reduced in both Group III and IV with variable degree. These results suggest the gastroprotective activity of RTN in ethanol gastric injury which were mediated via suppression of gastric inflammation, oxidative stress and apoptosis besides enhancing of the antioxidant and the cytoprotective defenses.

Keywords: Rutin; Gastritis; Pro-inflammatory Cytokines; cyclooxygenase II; DNA fragmentation; oxidative stress; histopathology.

1. INTRODUCTION

Gastritis is an inflammation, irritation, or erosion that occurs when the endogenous defensive mechanisms of mucosal barrier cannot properly protect the organ. Usually, exposure to exceed acid and pepsin causes insult on the gastrointestinal wall [1], for more than a century, peptic ulcer disease has been a major cause of morbidity and mortality [2]. The activated neutrophils will increase the production of pro-oxidative and pro-inflammatory enzymes and free radicals which lead to oxidative burst [3]. On the other hand, cytokines such as tumor necrosis factor-α (TNF-α) and interleukin-6 (IL-6) play important roles in the pathogenesis of acute gastric lesions induced by ethanol [4].

Administration of absolute ethanol into the gastric lumen induced gross lesions in the glandular part of the stomach [5]. Intragastrically administered Ethanol rapidly penetrates the gastrointestinal mucosa, causing

membrane damage, exfoliation of cells and gastritis. The increase in mucosal permeability together with the release of vasoactive products from mast cells, macrophages and blood cells may lead to vascular injury, necrosis and ulcer formation. Thus, generation of free radicals by the metabolism of arachidonic acid, platelets, macrophages, and smooth muscle cells has been suggested as one of the mechanisms responsible for gastro duodenal injury [6]. The effects of alcohol on the gastric mucosa are dose-dependent, and the damage appears as early as 30 minutes after ingestion and reaches a peak at about 60 minutes [7].

Oxidative stress and depletion of anti-oxidants have been considered a crucial step in alcohol-induced gastritis and so they have been widely investigated in a number of studies [8]. Overproduction of reactive oxygen species (ROS) has been concerned as one of the major pathogenic factors that directly results in oxidative damage, including lipid peroxidation, protein oxidation, and DNA damage, which can lead to cell death [9].

Rutin (a quercetin-rhamnoglucoside) is a glycosylated conjugate of quercetin (quercetin- 3-rutinoside) is one of the most common native flavonoids occurring mainly in glycosidic forms [10]. Also, it is a powerful antioxidant [11] with anti-inflammatory activity [12]. Moreover, a series of complexes of this ligand display an enhancement of free radical scavenger ability [13]. Accordingly, the present study was planned to investigate the effect of RTN against ethanol-induced gastritis in rats. Also, to determine whether RTN when administered to gastritis in rats would attenuate the oxidative stress in gastric tissue, beneficial for the prevention and treatment of gastritis complications and provide therapeutic alternatives for repairing gastric mucosal damage.

2. MATERIALS AND METHODS

2.1 Experimental animals:

Fourty white male albino rats of 12-16 weeks old and weighting 200 - 250 gm were used in this study. Rats were housed in separated metal cages and kept at constant environmental and nutritional conditions throughout the period of experiment. The animals were fed on constant ration and water was supplied ad-libitum. The animals were left 14 days for acclimatization before the beginning of the experiment.

2.2 Rutin:

Rutin is pale yellow crystalline powder (purity ~99%) was manufactured by Sigma Chemical Co. (St. Louis, Mo, USA) and purchased from Schnelldorf, Germany through the Egyptian International Center for Import Cairo, Egypt.

RTN was dissolved with in propylene glycol solution and administered to rats in daily oral dose of 200 mg/kg body weight for 21 days [14].

2.3 Ethanol-induced gastritis:

Rats were fasted for 18 hours and allowed free access of water prior to the administration of ethanol for gastritis induction. All the rats except those of the control group orally administered with absolute ethanol at a dose of 1ml/rat [15].

2.4 Experimental design:

Rats were randomly divided into four main groups, placed in individual cages and classified as follow:

Group I (normal control group): received no drugs. This group was divided into 2 subgroups*:*

- Subgroup (a): Included 6 rats sacrificed at the 15th day of the experiment, served as the normal control rats for early gastritis group.
- Subgroup (b): Included 6 rats sacrificed at the 22th day of the experiment, served as the normal control rats for non-treated late gastritis group.

Group II (gastritis non-treated group): Included 12 rats, administrated once orally with 1ml/rat absolute ethanol for induction of gastritis. This group was divided into 2 subgroups*:*

- Subgroup (a): Consisted of 6 rats, served as early gastritis non-treated group, for comparison with RTN protected group. This group received absolute ethanol at a dose of (1ml/rat) on empty stomach and the rats were sacrificed one hour later of ethanol administration*.*
- Subgroup (b): Consisted of 6 rats served as late gastritis non-treated group, for comparison with RTN treated group. This group received absolute ethanol at a dose of (1ml/rat) on empty stomach and the rats were left free and sacrificed 7 days later of ethanol administration.

Group III (RTN protected group): Comprised 8 male rats received RTN (200 mg/kg body weight/day) orally for 14 days prior absolute ethanol administration. One hour after the administration of ethanol the animals were sacrificed.

Group IV (RTN treated group): Included 8 male rats received RTN orally(200 mg/kg body weight) for 14 days before ethanol administration and the treatment were continued with RTN for 7 days later.

2.5 Sampling:

Blood samples and tissue specimens (gastric tissues) were collected one hour after administration of ethanol in normal control group (subgroup a), gastritis non-treated group (subgroup a) and RTN protected gastritis group at the 15th day from the onset of treatment with RTN. Also, blood samples and tissue specimens (gastric tissues) were collected after 21days from the onset of treatment with RTN in normal control group (subgroup b), gastritis non-treated group subgroup (b) and RTN treated gastritis group.

2.5.1 Blood samples:

Blood samples for serum separation were collected by ocular vein puncture at the end of each experimental period in dry, clean, and screw capped tubes and serum were separated by centrifugation at 2500 r.p.m for 15 minutes .The clean, clear serum was separated by

automatic pipette and received in dry sterile samples tube and kept in a deep freeze at -20°C until used for subsequent biochemical analysis. All sera were analyzed for the following parameters: Nitric oxide (NO), Sialic acid (SA), tumor necrosis factor-alpha (TNF-α), interleukin-6 (IL-6) and L- Malondialdehyde (L-MDA).

2.5.2 Tissue samples (gastric tissue):

After 14 and 21 days of RTN administration the rats were sacrificed by cervical decapitation. The stomach was quickly removed, and opened along the greater curvature using a scrapper, cleaned by rinsing with cold saline and stored at -20°C for subsequent biochemical analyses. Moreover, gastric tissue specimens were taken from different parts of the stomach for histopathological examination.

2.5.2.1 Gastric tissue preparation for biochemical analysis:

Briefly, gastric tissues were cut, weighted and minced into small pieces, homogenized with a glass homogenizer in 9 volume of ice-cold 0.05 mM potassium phosphate buffer (pH7.4) to make 10% homogenates. The homogenates were centrifuged at 6000 r.p.m for 15 minutes at 4°C then the resultant supernatant were used for the determination of the following parameters: superoxide dismutase (SOD), catalase (CAT) and glutathione peroxidase (GPx), glutathione reductase (GR), L- Malondialdehyde (L-MDA), nuclear factor kappaB p65 (NF-KB p65), interleukin-6 (IL-6), cyclooxygenase-II (COX-2), reduced glutathione (GSH), vitamin C, myeloperoxidase (MPO) and DNA fragmentation.

2.5.2.2 Gastric tissue preparation for Histopathological examination:

Gastric tissue specimens were taken from different parts of the stomach for histopathological examination. The specimens were preserved in 10% buffered neutral formalin. The fixed tissue were rinsed in tap water, dehydrated through graded series of alcohols, cleared in xylene and embedded in paraffin wax. 5 µm thick sections were cut and stained with hematoxylin and eosin (H&E) (Bancroft and Stevens, 1996)[16] and then the tissues were examined and evaluated by light microscopy.

2.6 Biochemical analysis:

Serum NO, SA, TNF-α, IL-6 and gastric tissue vitamin C, L-MDA, GPx, SOD, CAT, GR, GSH, DNA fragmentation, NF-KB p65, IL-1β, COX-2 and MPO were determined according to the methods described by Vodovotz, (1996) [17]; Human Sialic acid (SA) Elisa kit (Cat. no. CSB- E09605h); Beyaert and Fiers, (1998) [18]; Chan and Perlstein, (1987) [19]; Mesbah *et al.,* (2004) [20]; Rat Vitamin C, VC ELISA kit (Cat .No.E0913r); Gross *et al*., (1967) [21]; Kakkar *et al*., (1984) [22]; Luck, (1974) [23]; David and Richard, (1983) [24]; Moron *et al*., (1979) [25]; Shi *et al*., (1996) [26]; Rat Nuclear factor-kappaB p65 (NF-kappaB p65) ELISA Kit instruction(Cat.No. MBS814487); RayBio^R Rat IL-1beta ELISA Kit Protocol (Cat.No.ELR-IL1beta-001C); COX-2 ELISA Kit (Cat.No. E0699m) and Rat Myeloperoxidase ELISA kit (Kamiya Biomedical Company, Cat .No. K60345), respectively.

2.7 Statistical analysis:

The obtained data were statistically analyzed by one-way analysis of variance (ANOVA) followed by the Duncan multiple test. All analyses were performed using the statistical package for social science (SPSS, 13.0 software, 2009). Values of $P<0.05$ were considered to be significant.

3. RESULTS AND DISCUSSION

3.1 Effect of rutin pretreatment on some serum and gastric tissue parameters of ethanol-induced gastritis in rats:

The obtained data demonstrated in table (1) showed a significant decrease in serum NO and SA levels and gastric tissue GSH, vitamin C concentrations and antioxidant enzymes(GPx, SOD, GR and CAT) activities in ethanol-induced gastritis group (early gastritis). Meanwhile, the values of serum TNF-α, IL-6, L-MDA levels and gastric tissues DNA fragmentation, NF-KB p65, IL-1β and L-MDA concentrations in addition to MPO and COX-2 activities were significantly increased in ethanol-induced gastritis group (early gastritis)in rats when compared with normal control group. Pretreatment with rutin in gastritis–induced rats resulted in a significant increase in serum NO and SA concentrations, and in gastric tissue GPx, SOD,CAT and GR activities, GSH and vitamin C levels. Meanwhile, L-MDA, DNA fragmentation, NF-KB p65, TNF-α, IL-6, IL-1β levels, COX and MPO activities were significantly decreased in protective period when compared with early gastritis non- treated group.

3.2 Effect of rutin treatment on some serum and gastric tissue parameters of ethanol-induced gastritis in rats:

The obtained data presented in table (2) revealed that, a significant decrease in serum NO, SA and in gastric tissue GSH and vitamin C concentrations, GPx, SOD, GR and CAT activities with a marked increase in serum TNF-α, IL-6, L-MDA levels and in gastric tissues DNA fragmentation, NF-KB p65, IL-1β and L-MDA concentrations as well as MPO and COX-2 activities were observed in gastritis-induced rats (late gastritis) when compared with normal control group. Administration of rutin to ethanol–induced gastritis in rats resulted in a significant increase in serum NO and SA levels and in gastric tissue GSH, vitamin C levels, GPx, SOD and CAT activities. However, rutin treatment to ethanol induced gastritis (late gastritis) in rats exhibited a significant decrease in serum TNF-α and IL-6 and in gastric tissue L-MDA, DNA fragmentation, NF-KB p65, IL-1β levels, COX-2 and MPO activities when compared with late gastritis non- treated group.

Table 1: Effect of pretreatment with rutin on some serum and gastric tissue parameters of ethanol-induced gastritis in rats.

Protective period			
Parameters / Experimental groups	Control Normal group	Gastritis induced group	Gastritis + RTN protected group
NO (mmol/L)	148.94 ± 2.60[a]	76.06 ± 2.19[c]	84.27 ± 3.21[c]
SA (mg/ ml)	55.87 ± 1.63[a]	12.64 ± 0.93[d]	28.28 ± 2.02[c]
GPx (ng/ g.tissue)	51.84 ± 0.91[a]	22.32 ± 0.68[e]	30.63 ± 1.07[d]
SOD (u/g.tissue)	21.18 ± 0.40[a]	12.80 ± 1.00[d]	14.92 ± 1.03[cd]
CAT(mmol/g.tissue)	66.15 ± 1.00[a]	30.00 ± 0.92[d]	46.67 ± 1.05[c]
GR (ng /g tissue)	3.66 ± 0.13[a]	1.83 ± 0.07[c]	2.19 ± 0.13[bc]
L-MDA (mmol/g.tissue	57.09 ± 0.55[d]	111.61 ± 0.72[a]	74.54 ± 7.88[bc]
GSH (ng/g.tissue)	9.59 ± 0.79[a]	1.95 ± 0.54[d]	6.58 ± 0.75[b]
Vitamin C (ng / g tissue)	40.38 ± 1.00[a]	16.45 ± 0.73[d]	23.74 ± 1.50[c]
DNA-fragmentation	96.25 ± 2.63[e]	1390.00 ± 4.22[a]	1017.31 ± 42.65[b]
(cells/well. tissue)	5.78 ± 0.14[c]	14.32 ± 0.68[a]	12.74 ± 0.52[a]
MPO (ng/g.tissue)	1.89±0.13[b]	7.92±0.98[a]	4.11±1.26[b]
NF-KB p65 (ng/g.tissue)	25.87±1.68[c]	81.81±0.76[a]	55.38±4.26[b]
TNF-α (pg/ml)	16.50±1.47[c]	132.07±1.25[a]	106.67±5.20[a]
IL-6 (pg/ml)	59.90±2.26[c]	478.50±3.34[a]	239.82±40.76[b]
IL-1β (pg/g.tissue)	0.26±0.07[c]	3.92±0.53[a]	3.37±0.21[a]

Data are presented as (Mean ± S.E). S.E = Standard error.
Mean values with different superscript letters in the same row are significantly different at (P<0.05).

Table 2: Effect of rutin treatment on some serum and gastric tissue parameters of ethanol-induced gastritis in rats.

Treatment period			
Parameters / Experimental groups	Control Normal group	Gastritis induced group	Gastritis + RTN treated group
NO (mmol/L)	163.38 ± 2.01[a]	55.63 ± 2.12[c]	102.05 ± 13.99[b]
SA (mg/ml)	51.14 ± 1.20[a]	20.80 ± 0.66[d]	27.69 ± 2.16[c]
GPx (ng/ g.tissue)	40.88 ± 0.97[a]	26.27 ± 0.84[d]	29.88 ± 0.90[c]
SOD (U/g.tissue)	24.49 ± 0.84[a]	12.06 ± 0.28[d]	13.28 ± 0.95[d]
L-MDA (mmol/ml)	66.93±1.90[d]	167.74±1.63[a]	139.14±11.92[b]
CAT(mmol/g.tissue)	63.46 ± 1.55[a]	35.36 ± 1.01[d]	43.85 ± 1.62[cd]
GR (ng /g tissue)	3.83 ± 0.16[a]	1.40 ± 0.11[b]	2.11 ± 0.30[b]
L-MDA (mmol/g.tissue)	71.26 ± 1.07[c]	128.39 ± 1.30a	94.95 ± 6.01[b]
GSH (ng/g.tissue)	10.98 ± 1.02[a]	3.78 ± 0.39[c]	5.46 ± 0.66[c]
Vitamin C (ng /g. tissue)	38.82 ± 0.47[a]	20.00 ± 0.66[c]	23.66 ± 1.80[c]
DNA-fragmentation (cells/well tissue)	17.50 ± 1.36[d]	1015.00 ± 2.13[a]	835.38 ± 58.16[b]
MPO (ng/g.tissue)	3.12 ± 0.14[d]	12.76 ± 0.77[a]	11.41 ± 0.58[a]
NF-KB p65 (ng/g.tissue)	1.40±0.16[b]	5.98±0.53[a]	2.11±0.28[b]
TNF-α (pg/ml)	30.98±0.26[d]	89.80±1.60[a]	65.77±3.19[b]
IL-6 (pg/ml)	24.07±1.09[b]	108.03±1.28[a]	84.26±8.92[a]
IL-1β (pg/g.tissue)	22.70±0.24	328.04±2.27[a]	189.74±9.27[b]
COX-2 (ng/g.tissue)	1.33±0.13[c]	4.28±0.54[a]	3.03±0.18[b]

Data are presented as (Mean ± S.E). S.E = Standard error.
Mean values with different superscript letters in the same row are significantly different at (P<0.05).

3.3 Histopathological results:

The microscopical examination of the stomach of control rats showing normal histological structure of the glandular epithelium of the gastric mucosa of the rats. The histopathological examination of the stomach of rats obtained after one hour from absolute ethanol (1ml/rat) administration from showed congestion of the blood vessels and few leukocytic infiltrations (Fig. 1A). Furthermore, mild desquamations of the epithelial cell lining of the gastric mucosa with focal leukocytic aggregation in the tunica submucosa were seen (Fig. 1B). Moreover, few mononuclear leukocytic cellular infiltrations were seen in between the glandular epithelium. Severe congestion of the blood vessels of the stomach in the tunica muscularis together with few leukocytic infiltrations was also detected.

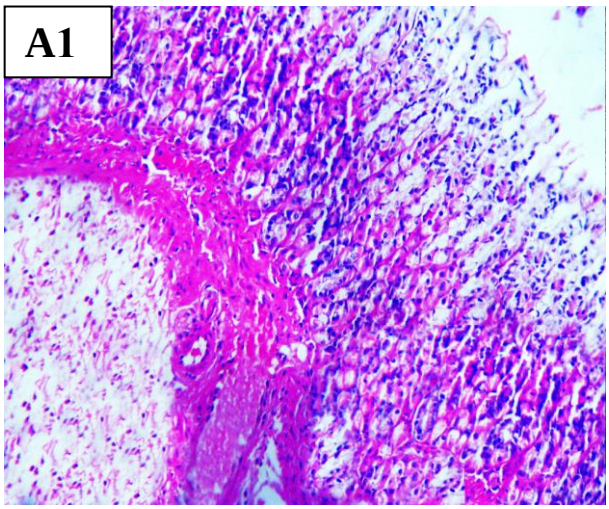

stomach of rats received 1ml of absolute ethanol orogastrically and sacrificed after one hour of administration showing congestion of the blood vessels and few leukocytic infiltration. (H & E, x200).

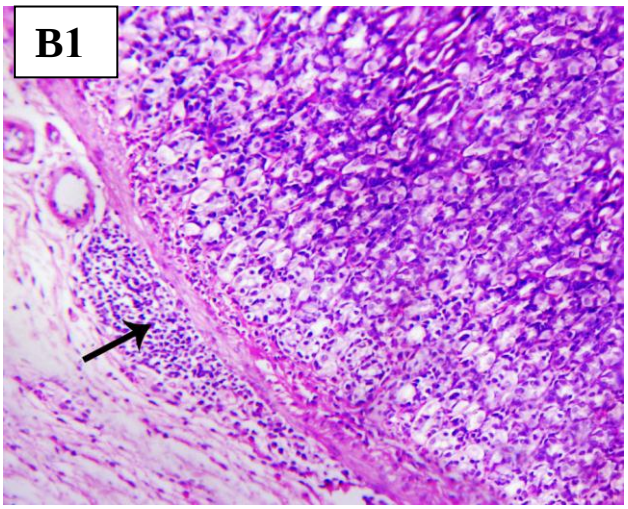

stomach of rats received 1ml of absolute ethanol orogastrically and sacrificed after one hour of administration showing focal mononuclear cellular aggregation in the tunica muscularis (arrow). (H & E, x200).

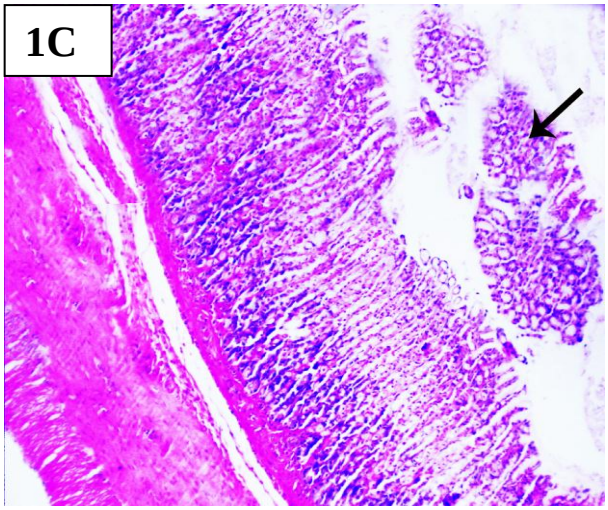

stomach of rats received 1ml of absolute ethanol orogastrically and sacrificed after seven days of administration showing severe desquamation of the lining epithelium of gastric mucosa (arrow). (H & E, x100).

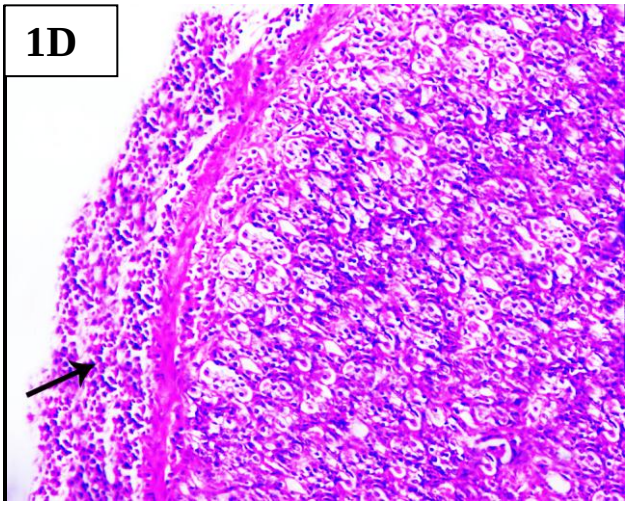

stomach of rats received 1ml of absolute ethanol orogastrically and sacrificed after seven days of administration showing heavy leukocytic infiltration under the tunica muscularis (arrow). (H & E, x200).

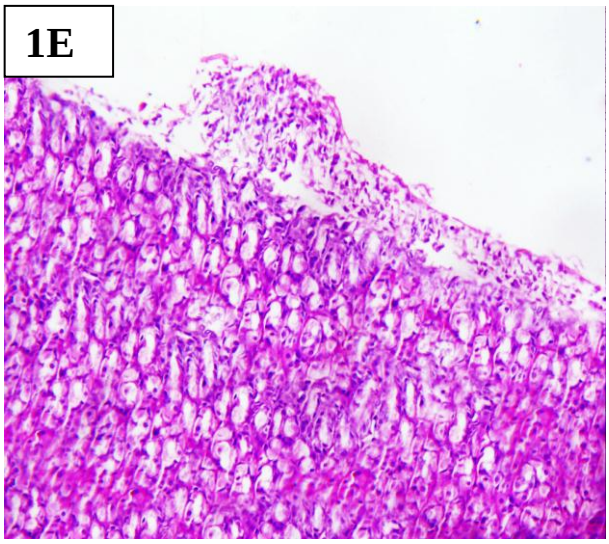

Stomach rats protected with Rutin (200 mg/kg body weight of rat) daily orogastrically for forteen days then received 1ml of absolute ethanol orogastrically and sacrified after one hour of administration showing mild desquamation of epithelial cell lining of gastric mucosa. (H & E, x100).

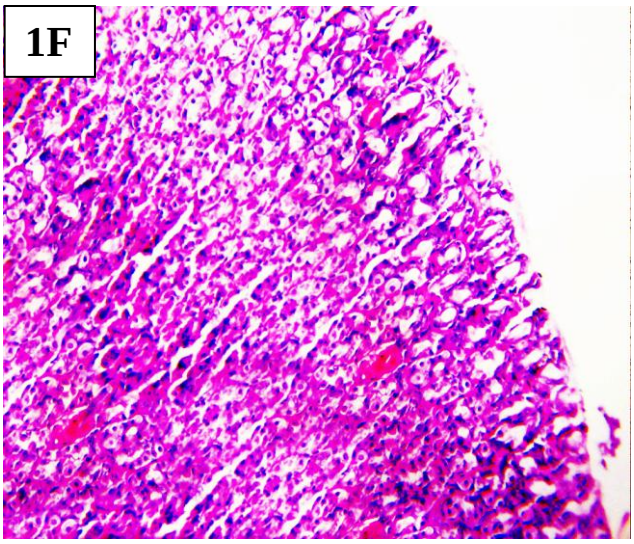

Stomach of rats treated with(200mg/kg body weight of rat) Rutin daily orogastrically for seven days, its gastric mucosa showing mild degeneration of epithelial cell lining of gastric mucosa with mild congestion of the gastric blood vessels. (H & E, x200).

However, the histopathological examination of the stomach obtained after 7 days from ethanol administrations showing severe desquamation of the glandular epithelium lining of the gastric mucosa was also seen (Fig. 1C). The desquamated epithelium admixed with eosinophilic debris was seen in the gastric lumen. Moreover, heavy leukocytic mononuclear infiltration was also noticed under the tunica muscularis (Fig. 1D). Interestingly, the stomach of rats protected with RTN (200 mg/kg body weight/day) orally for 14 days prior absolute ethanol administration for one hour showed mild congestion of the gastric blood vessels with mild desquamation of the glandular epithelium lining of the gastric mucosa (Fig. 1E). In the meantime, the samples of the same group but collected after 7 days have mild desquamation of the glandular epithelium lining of the gastric mucosa with congestion of the gastric blood vessels (Fig. 1F).

The ethanol model is widely used to assess the protective and healing activity of many drugs in ulcer studies [27]. Due to its ability to reduce endogenous NO level and blood flow in gastric mucosa, which leads to a serious hemorrhagic necrosis and consequently depletes gastric mucus constituents [28], resulting in an increased flow of Na^+ and K^+, elevated pepsin secretion, loss of H^+ ions and histamine into the lumen [29].

A significant decrease in serum NO and SA concentrations were observed in ethanol-induced gastritis group in both protective and treatment period. Lower nitrites level in alcoholics than in control group might result from endothelium dysfunction, or decreased NOS reaction on stimuli [30], or NO consumption in free radicals reactions with peroxy-nitrites (ONOO-) overproduction [31], Potentially formed during NO reaction with free radicals overproduced during ethanol metabolism [32]. The levels of sialic acid were found to be reduced in ethanol treated gastritis. The decrease in the glycoprotein moieties in the gastric mucosa may be attributed to the decreased activity of defense mechanisms as a result of damage to the gastric mucosa [33]. A non-significant increase in serum nitric oxide concentration was observed in RTN protected gastritis group. Meanwhile, a significant increase in serum nitric oxide concentration was observed in RTN treated late gastritis groups compared with the gastritis non treated groups. These results are nearly similar to those reported by Olszanecki et al., (2002) [34] who reported that, treatment with RTN increased the level of NO concentration in gastric mucosal tissues by enhancing the activity of cNOS and inhibiting the activity of iNOS. Nitric oxide has an important role in maintaining gastric mucosal integrity. Inhibition of gastric NO formation decreases gastric blood flow, deprives the tissue of oxygen, and increases mucosal vulnerability to intragastric administration of irritants that mildly damage the gastric mucosa. The cumulative data thus show that endogenous NO is an essential protective factor in the pathogenesis of gastric injury induced by agents such as ethanol and iodoacetamide [35]. On another hand, continuously production of NO and superoxide anion is likely during inflammation and pathological conditions. They react together to form peroxynitrite. The scavenging effect on superoxide anion by NO may be a mechanism by which tissues of host are protected from the deleterious effects of superoxide and superoxide derived reactive oxygen species [36].

Sialic acid is the generic term given to a family of acetylated derivatives of neuraminic acid which occur mainly at terminal positions of glycoprotein and glycolipid oligosaccharide side-chains. In the present study RTN may be help in protection of gastric mucosa from ethanol-induced gastritis due to its positive effect on increasing serum sialic acid concentration in protective and treatment period. Mucus secretion is a crucial factor in the protection of gastric mucosa from the gastric lesions and has been regarded as an important defensive factor in the gastric mucus barrier. A decrease in the synthesis of sulphated mucus glycoprotein has been implicated in the etiology of gastritis [37]. Furthermore, a recent report indicated that the glycosidic linkage of sialic acid is a potential target for superoxide and other related ROS [38]. Mucin acts as a sacrificial scavenger for ^{-}OH and its protective function is exerted by the direct reaction with its sialic acids [39].

A significant decrease in gastric tissue GSH, vitamin C concentrations, GPx, SOD, GR and CAT activities were observed in ethanol-induced gastritis rats group in protective and treatment periods when compared with normal control group. Similarly, Hussein et al, (2014) [40] reported that, a significant decrease in gastric tissue GPX, SOD and CAT activities and vitamin C level were observed in protective and treatment period in ethanol-induced ulcerated rats group. Vitamin C is a water-soluble antioxidant present in the circulation and tissues [41]. It scavenges and destroys the free radicals in combination with glutathione. The observed decreased in these antioxidants in gastritis rats may be due to increased utilization in scavenging the free radicals[42].

In the current research, the microsopical examination of the gastric tissue obtained from ethanol administered group revealed desquamation of the lining epithelium of gastric mucosa in combination with leukocytic cellular infiltration in sub mucosa. These findings could be related to the release of oxygen-derived free radicals (ROS) that has drawn attention as a possible pathogenic factor of gastric mucosal injury associated with ethanol consumption [43]. To scavenge ROS, gastric cell have several enzymatic and non-enzymatic antioxidants including CAT, SOD, GPx, and endogenous GSH, but excessive generation of ROS enhance lipid peroxidation and depletes these

antioxidants enzymes. Superoxide produced by peroxidase in the stomach tissues might damage cell membranes and cause gastritis by increasing MDA level [44]. SOD is considered as the first line of defense against the deleterious effects of oxygen radicals in the cells and it scavenges ROS by catalyzing the dismutation of superoxide to H_2O_2 [45]. There is evidence to indicate that ethanol significantly depresses SOD activity [46].

Ethanol inhibited SOD and thus superoxide radicals could not convert to H_2O_2.The inhibition of SOD activity may result in an increased flux of superoxide in cellular compartments which may be the reason for the increased lipid peroxidative indices. In this context, the present results are nearly similar with that reported by Megala and Geetha, (2010) [47]. Moreover, ethanol decreased the gene expression and the activity of SOD in the gastric mucosa, suggesting that the suppression of key mucosal antioxidant enzyme, along with the elevation of lipid peroxidation, play an important role in the pathogenesis of these lesions [48]. In the present study, SOD activity decreased significantly in the ethanol treated rats group, which might be due to an excessive formation of superoxide anions. These excessive superoxide anions might inactivate SOD and decrease its activity. In the absence of adequate SOD activity, superoxide anions are not dismuted into H2O2, which is the substrate for the H_2O_2 scavenging enzymes CAT and GPx. These result in inactivation of the H_2O_2 scavenging enzymes CAT and GPx, leading to a decrease in their activities [49]. The decrease in GPx activity may attenuate the radical scavenging function [50], GR accelerating the conversion of GSSG to GSH and enhancing the detoxification of reactive metabolites by conjugation with GSH [49]. Moreover, glutathione peroxidase plays a primary role in minimizing oxidative damage. (GPx), an enzyme with selenium and Glutathione-s-transferase (GST) works together with glutathione in the decomposition of H_2O_2 or other organic hydroperoxides to non-toxic products at the expense of reduced glutathione [51]. Reduced activities of GPx may result from radical–induced inactivation and glycation of the enzyme [52]. Also, decline in the GPX activity may be due to over production of free radical induced cells damage. It is now known that, when there is an imbalance between free radical production and antioxidant defenses, 'oxidative stress' occurs resulting in deregulation of cellular functions [53]. On the other hand, the decrease in GR activity may be due to the over production of free radical and hydrogen peroxide. GSH is required to maintain the normal reduced state and to counteract the deleterious effects of oxidative stress.

Pretreatment with RTN in gastritis-induced rats resulted in a non-significant increase in SOD and GR activities and significant increase in vitamin C and GSH levels, GPx and CAT activities in protective period. However, administration of RTN to ethanol–induced gastritis in rats exhibited significant increase in gastric tissue GPx activity with a non-significant increase in GSH and vitamin C levels, SOD, GR and CAT activities in treatment period when compared with control gastritis non- treated group. Antioxidant effects of RTN is based on that it increased the levels of non-enzymic antioxidants, decreased oxidative stress resulted in the restoration of glutathione levels in the plasma. Glutathione through its significant reducing power contributes to the recycling of other antioxidants such as vitamin C and vitamin E, that have become oxidized [54]. Vitamin C is an excellent hydrophilic antioxidant in plasma, because it disappears faster than other antioxidant when plasma is exposed to reactive oxygen species [55]. GSH is required to maintain the normal reduced state and to counteract the deleterious effects of oxidative stress. During the reduction of hydrogen peroxide, GSH is oxidized to GSSG. When GSSG levels are enhanced, the GSH-reductase activity was activated to convert GSSG in GSH [56]. The balance between these enzymes is important for the efficient removal of oxygen radicals from tissues [57]. Meanwhile, after administration of RTN the concentration of GSH increased and superoxide radicals decreased. Therefore, GR activity increased. In the present study, administration of RTN associated with increased SOD activity in gastric tissue. The enzymatic antioxidant defense systems are the natural protectors against lipid peroxidation. They include superoxide dismutase and glutathione peroxidase [58]. Superoxide dismutase is the antioxidant enzyme that catalyses the dismutation of the highly reactive superoxide anion to O2 and to the less reactive species H_2O_2. Peroxide can be destroyed by CAT or GPX reactions [59]. First, SOD converts the superoxide anion to hydrogen peroxide in a cellular antioxidant reaction. Thereafter, GSH-Px detoxify hydrogen peroxide produced [60]. It has been suggested that RTN can reduce oxidized GSH and increase the GSH status, which in turn exhibits increased free radical scavenging property, so RTN indirectly influences the activity of SOD thereby preventing the deleterious effect of superoxide radical formed, That causes activation of SOD, GPx and CAT [61].Glutathione and glutathione- related enzymes play a key role in protecting the cells against the damaging effects of reactive oxygen species. Intracellular GSH can act as a reductant, reducing hydrogen peroxide and lipid hydroperoxides directly to H_2O, a reaction catalyzed by GSH-Px. Depletion of intracellular GSH, under conditions of continuous intracellular oxidative stress, leads to oxidation and damage of lipids, proteins and DNA by the reactive oxygen species [62]. Glutathione has a very important role in protecting against oxygen-free radical damage by scavenging of hydroxyl radicals. RTN restored the reduced glutathione levels that were depleted by ethanol in gastric mucosa. This result was supported by Bishnoi et al., (2007) [63] who reported that, RTN increases the glutathione level that was reduced after haloperidol treatment.

A significant increase in gastric tissue DNA fragmentation, tissue and serum L-MDA levels and MPO activity were observed in gastritis-induced rats in

protective and treatment period when compared with normal control group. Similarly, Hussein et al., (2014) [40]reported that, a marked increase in gastric tissue L-MDA, DNA-fragmentation and MPO were observed in ethanol induced gastric mucosal damage in rats. Malondialdehyde is the final product of lipid peroxidation and is used to determine lipid peroxidation levels [64]. There is consensus that the deleterious effects of ethanol on gastric mucosa are consequence of enhanced lipid peroxidation. The presence of oxygen free radicals that cause lipid peroxidation have been reported in the pathogenesis of gastric mucosal lesions induced by ulcer inducing agents such indomethacin, alcohol and aspirin in rats[65]. Free oxygen radicals initiate lipid peroxidation by removing one hydrogen atom from polyunsaturated fatty acids with the subsequent formation of hydro peroxides. As a result of these reactions, the membrane fluidity and membrane integrity of cells are impaired, leading to disintegration of cells and cell death. These subcellular structures that are released into the extracellular environment trigger several inflammatory events and further worsen the ongoing damage [66]. RTN administration to gastritis induced rats group resulted in significant decrease in gastric tissue and serum L-MDA concentration when compared with gastritis non treated group. Free radicals react with lipids in cell membranes and form lipid peroxides and this changes the integrity of cells. RTN, being an anti-lipoperoxidant agent, inhibits formation of lipid peroxides [67]. Also, Annapurna et al., (2009) [68] reported that, the two natural bioflavonoids, rutin and qurecetin, showed to decreased MDA levels and increased antioxidant enzyme levels in cardiac ischemia reperfusion injury. The mechanism of reperfusion injury induced oxidative stress is similar in cardiac reperfusion injury and testicular ischemia reperfusion injury.

The present study indicates that EtOH exposure increases the apoptotic DNA fragmentation ratio of the gastric mucosa, which seems to be responsible of severe injury. Furthermore, it was investigated that ROS may cause DNA-fragmentation [69]. Under normal physiological conditions, the balance between gastric epithelial cell proliferation and death is of great importance in maintaining gastric mucosal integrity. Since, the balance between cell apoptosis and cell proliferation has important role to keep the gastric mucosa healthy [70]. Since, the gastric epithelial cells proliferate in the lower part of the glandular neck and migrate up the crypt towards the surface and then are shed into the lumen by apoptosis [71]. Disturbance of this balance could result in either cell loss, leading to mucosal damage and gastritis, or cell accumulation, leading to cancer development [72]. The gastric mucosal hemorrhage evoked by extra amounts of alcohol is initiated by the microcirculatory damage of the gastrointestinal mucosa, namely a disruption of the vascular endothelium resulting in increased vascular permeability, edema formation and epithelial lifting. It has been shown that EtOH dramatically increases the low level of spontaneous apoptosis in gastric tissues which normally occurs to protect against the survival and expansion of genetically damaged cells [73]. RTN administration to gastritis induced rats resulted in significant decrease in gastric tissue DNA fragmentation percentage when compared with gastritis non treated group.RTN treatment, in the present study, suppressed the high percentage of DNA fragmentation in the gastric mucosa, while gastric epithelial integrity was maintained. Similarly, Fang et al., (2008) [74] reported that, treatment with RTN significantly reduced apoptotic cell death caused by oxidative stress (H_2O_2) through a significant reduction in pro-apoptotic gene (Bax) expression and increased anti-apoptotic gene (Bcl-2) expression in H9c2 cells treated with H_2O_2 in vitro. Also, Shakeerabanu et al., (2011) [75] provide evidence that, quercetin enhances the healing of gastric tissue damage by increasing PH, decreasing of (acidity, acid output, pepsin concentration), as well as by its antiapoptotic activity.

Myeloperoxidase is an essential enzyme for normal neutrophil function, released into extracellular fluid as a response to various stimulatory substances. MPO activity is considered as an index for the evaluation of neutrophil infiltration. In the present study, a significant increase in MPO activity was observed in ethanol-induced gastritis group. The elevated activity of MPO in the gastric mucosa indicates oxidative injury induced by ethanol involves the contribution of neutrophil accumulation [33]. The increase in enzyme activity level may be associated with increase in the levels of neutrophil infiltration and H_2O_2 in the gastric damaged tissues administered with ethanol [47]. Also, one mechanism in the pathogenesis of mucosal lesions provoked by ethanol may be circulating neutrophils [76]. The leukocytes might create gastritis through various mechanisms, such as the production of reactive oxygen metabolites or the release of proteases and lipid mediators [77]. Moreover, activated neutrophils produce many enzymes and free radicals that damage the gastric mucosa, neutrophil is considered as an aggressive factor in gastritis [78].

The gastric injury induced by EtOH involves toxic oxygen metabolites. Since one of the sources of oxygen radicals in gastritis induced by EtOH in rats seems to be the neutrophils [79]. In the present study, the role of neutrophils was assessed by tissue-associated MPO activity, demonstrating a significant elevation in both periods of gastritis.RTN administration to gastritis induced rats group resulted in a non-significant decrease in gastric tissue MPO activity in protective and treatment periods when compared with gastritis non treated group. The obtained results are nearly similar to those reported by Pincemail et al., (1988) [80] who recorded that, RTN inhibits neutrophil infiltration as demonstrated from reduction of human myeloperoxidase activity both with purified enzyme and in stimulated human neutrophils. Moreover, RTN was reported to enhance the activity of cNOS leading to increase in the nitric oxide levels in gastric mucosal

tissues. cNOS-derived nitric oxide improves the mucosal blood flow and tissue perfusion leading to attenuation of neutrophil infiltration [34]. Furthermore, RTN administration was previously shown to offer gastric mucosal protection against ethanol-induced gastric lesions by a neutrophil-dependent mechanism [11].

The nuclear transcription factor NF-kB is a key regulator of the inducible expression of many genes involved in immune and inflammatory responses in the gut. Stimuli such as oxidative stress, cytokines (IL-1, IL-6, TNF-α), bacteria and viruses can release NF-KB to allow translocation to the nucleus [81].Chronic ethanol treatment elevates endotoxin level, and endotoxin activates kupfer's cells to produce free radicals via NADPH oxidase. The free radicals activate nuclear factor –kappa B (NF-KB), leading to an increase in production of tumor necrosis factor alpha (TNF-α), followed eventually by tissue damage [82].The imbalance between gastro toxic agents and protective mechanisms resulted in an acute inflammation. The interleukin-1 beta (IL-1β) and TNF-α are major pro-inflammatory cytokines, playing important role in production of acute inflammation [83]. This acute inflammation is accompanied by neutrophils infiltration of gastric mucosa. Neutrophils produce superoxide radical anion ($O2^{\bullet-}$), which belongs to group of ROS [84]. A significant decrease in gastric tissue NF-KB p65, IL-1β and serum TNF-α and a non significant decrease in serum IL-6 were observed in gastritis-induced rats in protective and treatment period when compared with normal control group. Similarly, Doyle and O'Neill (2006) [85]reported that, treatment with the phenol derivative of rutin (DHT) attenuated the movement of activation NF-KB into cellular nucleus which is controlled by the targeted phosphorylation and subsequent degradation of IKB. Also, Spranger et al., (2003) [86] described that, DHT reduced the generation of proinflammatory cytokines IL-6 and IL-1β. Moreover, Tracey and Cerami, (1994) [87]suggested that, RTN treatment significantly decrease TNF-α and IL-1β.

Prostaglandins (PGs) are involved in a variety of physiological processes in the stomach, including acid secretion,production of mucus and mucosal blood flow [88].Cyclooxygenase (COX), the key enzyme for PG production, exists as two isozymes referred to as COX-1 and COX-2. COX-1 is constitutively expressed in normal gastric mucosa and generates PGs involved in the maintenance of essential physiological functions [89], while COX-2, characterized by a rapid inducibility in response to various proinflammatory stimuli, is responsible for pathological PG production at inflammatory sites [90].A non-significant decrease in gastric tissue COX-2 was observed in gastritis-induced rats in protective period and a significant decrease in gastric tissue COX-2 was observed in gastritis-induced rats in treatment period when compared with normal control group. Similarly, Lee et al., (2012) [91] recorded that, the phenol derivative of rutin (DHT) significantly suppressed the LPS-induced production of cyclooxygenase II (COX-2), nitric oxide (NO) and iNOS

4. CONCLUSION

In conclusion, the present study demonstrated that, RTN possesses significantly gastroprotection and treatment effects against gastritis and oxidative damage in gastric tissue induced by ethanol in rats. Since, RTN was able to ameliorate serum biochemical parameters, enzymatic and non-enzymatic antioxidant defense system, and mucus secretion and prevent DNA fragmentation in gastric tissue as well as improving the integrity of gastric tissue. Based on the data of the current study, the effect of RTN against ethanol-induced gastric lesions can be attributed to the inhibitory effects on neutrophil infiltration, and its reduction of inflammatory markers as well as reduction of the severity of the pathological changes in the gastric tissue in comparison to ethanol treated group. We recommended that, administration of diet rich in the antioxidant flavonoid RTN is very important for protection of different body tissue, especially gastric tissue, against oxidative stress or even inflammation or erosion.

5. REFERENCES

1. Khazaei, M. , Salehi, H. (2006). Protective effect of Falcaria vulgaris extract on ethanol induced gastric ulcer in rat. Iranian Journal of Pharmacology and Therapeutics, 5,(1) pp: 43-46.
2. Umamaheswari, M., Asokkumar, K., Rathidevi, R. et al., (2007). Antiulcer and in vitro antioxidant activities of Jasminum grandiflorum L. J Ethnopharmacol. 110,464-470.
3. Chatterjee, M., Saluja, R., Kanneganti, S. et al., (2007). Biochemical and molecular evaluation of neutrophil NOS in spontaneously hypertensive rats. Mol. Cell. Biol. 53, 84–93.
4. Choi, J.I., Raghavendran, H.R.B., Sung, N.Y. et al., (2010). Effect of fucoidan on aspirin-induced stomach ulceration in rats. Chem. Biol. Interact. 183, 249–254.
5. Natale, G., Lazzeri, G. , Blandizzi, C. (2001). Seriate histomorphometry of whole rat stomach: an accurate and reliable method for quantitative analysis of mucosal damage. Toxicol Appl Pharmacol. 174:17-26.
6. Pihan, G., Regillo, C. , Szabo, S. (1987). Free radicals and lipid peroxidation in ethanol- or aspirin-induced gastric mucosal Injury. Dig Dis Sci, 32, 1395–1401.
7. Knoll, M.R., Kolbel, C.B., Teyssen, S. et al., (1998). Action of pure ethanol and some alcoholic beverages on the gastric mucosa in healthy humans: a descriptive endoscopic study. Endoscopy 30:293-301.
8. Arafa, H.M. , Sayed-Ahmed, M.M. (2003). Protective role of carnitine esters against alcohol-induced gastric lesions in rats. Pharmacological Research, 48, (3)pp. 285-290.
9. Ali, T. , Harty, R.F. (2009). Stress - Induced Ulcer Bleeding in Critically Ill Patients. Gastroenterology Clinics of North America, 2, pp: 245–265.
10. 10.Kamalakkannan, N. , Prince, P.S.M. (2006). Antihyperglycaemic and Antioxidant Effect of Rutin, a Polyphenolic Flavonoid, in Streptozotocin-Induced DiabeticWistar Rats. Basic & Clinical Pharmacology & Toxicology, 98,97-103.
11. La Casa, C., Villegas, I., Lastra, C.A. et al., (2000). Evidence for protective and antioxidant properties of rutin, a natural flavone, against ethanol induced gastric lesions. J Ethnopharmacol 71:45–53.
12. Han, Y. (2009). Rutin has therapeutic effect on septic arthritis caused by Candida albicans. Int. Immunopharmacol., 9: 207–211.
13. 13. Kostyuk, V.A., Potapovich, A.I., Kostyuk, T.V. et al., (2007). Metal complexes of dietary flavonoids: evaluation of radical scavenger properties and protective activity against

oxidative stress in vivo. Cell. Mol. Biol., 53, 62–69.
14. Abdel-Raheem, I.T. (2010). Gastroprotective Effect of Rutin against Indomethacin-Induced Ulcers in Rats. Basic & Clinical Pharmacology & Toxicology, 107, 742–750.
15. Şehirli, O., Tatlıdede, E., Yüksel, M. et al., (2008). Antioxidant Effect of Alpha-Lipoic Acid against Ethanol-Induced Gastric Mucosal Erosion in Rats. Pharmacology, 81;173–180.
16. Bancroft, J.D. , Stevens, S.A. (1996). Theory and Practice of Histological Techniques. Churchill-Livingstone, New York. 435-470.
17. Vodovotz, Y. (1996). Modified microassay for serum nitrite and nitrate. Bio Techniques, 20, 390-394.
18. Beyaert, R. , Fiers, W. (1998). Tumor Necrosis Factor and Lymphotoxin. In Cytokines, A. R. M.-S. a. R. Thorpe, eds. Academic Press,San Diego, p. 335-360.
19. Chan, D.W. , Perlstein, N.T. (1987). Immunoassay: A Practical Guide, Eds, Academic Press: New York, p71.
20. Mesbah, L., Soraya, B., Narimane, S. et al., (2004). protective effect of flavonides against the toxicity of vinblastine cyclophosphamide and paracetamol by inhibition of lipid – peroxydation and increase of liver glutathione. Haematol.7; (1): 59-67.
21. Gross, R.T., Bracci, R., Rudolph, N. et al., (1967). Hydrogen peroxide toxicity and detoxification in the erythrocytes of newborn infants. Blood, 29: 481–493.
22. 22. Kakkar, P., Das, B. , Viswanathan, P.N. (1984). A modified spectrophotometric assay of superoxide dismutase. Indian, J. Biochem Biophys, 21, 130-132.
23. Luck, H. (1974). Estimation of catalase. In: methods in enzymatic analysis. P: 885.
24. David, M. , Richard, J.S. (1983). Glutathione reductase. In: Methods of Enzymatic Analysis. Bermeyer, Hans, Ulrich, Jr. (Eds.), 258–265.
25. Moron, M.S., Depierre, J.W. , Mannervik, B. (1979). Levels of glutathione, glutathione reductase and glutathione S-transferase activities in rat lung and liver. Biochimica et Biophysica ACTA 582: 67-78.
26. Shi, B., De Girolami, U., He, J. et al., (1996). Apoptosis induced by HIV-1 infection of the central nervous system. J Clin Invest 98, 1979 - 1990.
27. Jong-il, C., Hanumatha, R.B.R., Nak-Yun, S. et al., (2010). Effect of fucoidan on aspirin-induced stomach ulceration in rats. Chem. Biol. Interact. 183: 249-254.
28. Kryger, G., Harel, M., Giles, K. et al., (2000). Structures of recombinant native and E202Q mutant human acetylcholinesterase complexed with the snake-venom toxin fasciculin-II. Acta Crystallogr D Biol Crystallogr. 56(Pt 11):1385-94.
29. Sandor, S. (1987). Mechanisms of mucosal injury in the stomach and duodenum: time-sequence analysis of morphologic, functional, biochemical and histochemical studies. Scand. J. Gastroenterol. 22, 21-28.
30. 30. Enomoto, N., Ikejima, K., Kitamura, T. et al., (2000). Alcohol enhances lipopolysacch-ide induced increases in nitric oxide production by Kupfer cells via mechanism dependent on endotoxin. Alcohol.Clin.Exp. Res. 24:55S-58S.
31. Banan, A., Fields, J.Z., Decker, H. et al., (2000). Nitric oxide and its metabolites mediate ethanol-induced microtubule disruption and intestinal barrier dysfunction. J. Pharmacol. Exp. Ther. 294, 997-1008.
32. Zima, T., Fialova, L., Mestek, O. et al., (2001). Oxidative stress, metabolism of ethanol and alcohol-related diseases. J. Biomed. Sci., 8, 59-70.
33. Amudhan, S.M. , Begum, H.V. (2008). Protective effect of areca catechu extract on ethanol induced gastric mucosal lesions in rats. Pharmacology online, 1, 97-106.
34. Olszanecki, R., Gebska, A., Kozlovski, V.I. et al., (2002). Flavonoids and nitric oxide synthase. J Physiol Pharmacol, 53,571–84.
35. Karmeli, F., Okon, E. , Rachmilewitz, D. (1996). Sulphydryl blocker induced gastric damage is ameliorated by scavenging of free radicals. 38, 826-831.
36. Beckman, J. S., Beckman, T. W., Chen, J. et al., (1990). Apparent hydroxyl radical production by peroxynitrite, implication for endothelial injury from nitric oxide and superoxide. Proc. Natl. Acad. Sci. USA, 87, 1620-1624.
37. Younan, F., Person, J., Allen, A. et al., (1982). Changes in the structure of the mucus gel in the mucosal surface of the stomach in association with peptic ulcer disease. Gastroenterology, 82, 827-31.
38. Eguchi, H., Ikeda, Y., Ookawara, T. et al., (2005).Modification of oligosaccharides by reactive oxygen species decreases sialyl lewis x-mediated cell adhesion. Glycobiology, 15: 1094–1101.
39. Ogasawaraa, Y., Namaia, T., Yoshinob, F. et al., (2007). Sialic acid is an essential moiety of mucin as a hydroxyl radical scavenger. 581, 2473–2477.
40. Hussein, S.A., El-senosy, Y.A. , Marwa, F. Hassan (2014).Gastro Protective, Antiapoptotic And Anti-Inflammatory Effect Of Alpha-Lipoic Acid On Ethanol Induced Gastric Mucosal Lesions In Rats. American Journal of Biochemistry and Molecular Biology, 4(2), 48-63.
41. Kucharz, E.J. (1992). The collagens, biochemistry and pathophysiology. Berlin: Springer-Verlag, 31-35.
42. Prakash, M., Gunasekaran, G. , Elumalai, K. (2008). Effect of earthworm powder on antioxidant enzymes in alcohol induced hepatotoxic rats. European Review for Medical and Pharmacological Sciences, 12, 237-243.
43. Smith, G.S., Mercer, D.W., Cross, J.M. et al., (1996). Gastric injury induced by ethanol and ischemia–reperfusion in the rat. Dig. Dis. Sci. 41, 1157–1164.
44. 44. Cadirci, E., Suleyman, H., Aksoy, H. et al., (2007). Effects of Onosma armeniacum root extract on ethanol-induced oxidative stress in stomach tissue of rats. Chem. Biol. Interact. 170, 40–48.
45. Okado-Matsumoto, A. , Fridovich, I. (2001). Subcellular distribution of superoxide dismutases (SOD) in rat liver: Cu-, Zn-SOD in mitochondria. J Biol Chem. 276; 38388-93.
46. Rukkumani, R., Aruna, K., Varma, P.S. et al., (2004). Comparative effects of curcumin and an analog of curcumin and PUFA induced oxidative stress. J Pharm Pharm Sci. 7;(2):274-83.
47. Megala, J. , Geetha, A. (2010). Gastro protective and antioxidant effects of hydro alcoholic fruit extract of pithecellobium dulce on ethanol induced gastric ulcer in rats. Pharmacology online 2: 353-372.
48. Brzozowski, T., Konturek, S.J., Kwiecien, S., Pajdo, R., Drozdowitz, D., Sliwowski, Z. and Muramatsu, M. (1998: a novel synthetic flavonoid derivative of sophoradin, with potent gastroprptective and ulcer healing activity. J. Physiol Pharmacol. 49, 83–98.
49. Panda, V., Ashar, H. , Srinath, S. (2012). Antioxidant and hepato-protective effect of Garcinia indica fruit rind in ethanol induced hepatic damage in rodents. Interdiscip Toxicol. 5(4): 207–213.
50. 50. Oh, S.I., Kim, C.I., Chun, H.J. et al., (1998). Chronic ethanol consumption affects glutathione status in rat liver. J Nutr, 128: 758-763.
51. 51. Bruce, A., Freeman, D. and James, C. (1982). Biology of disease – free radicals and tissue injury. Lab Invest, 47, 412.
52. Hodgson, E.K. , Fridovich, I. (1975). The interaction of bovine erythrocyte superoxide dismutase with hydrogen peroxide: inactivation of the enzyme. Biochemistry, 14 (24), pp 5294–5299
53. Bandyopadhyay, U., Das, D. , Banerjee, R.K. (1999). Reactive oxygen species, oxidative damage and pathogenesis. Curr Sci., 77(5), 658–665.
54. Kidd, P. M. (1997). Glutathione: systemic protectant against oxidative and free radical damage. Altern. Med. Rev. 2: 155–176.
55. Fri, B., England, L. , Ames, B. N. (1989). Ascorbate is an outstanding antioxidant in human blood plasma. Proc Natl Acad Sci USA, 86(16):6377–6381.
56. Cui, B., Liu, S., Lin, X. et al., (2011). Effects of Lycium Barbarum Aqueous and Ethanol Extracts on High-Fat-Diet Induced Oxidative Stress in Rat Liver Tissue. Molecules. 16(11):9116-28.
57. Kojo, S. (2004). Vitamin C, basic metabolism and its function as an index of oxidative stress. Curr Med Chem 11: 1041-1064.
58. Koppenol, W.H. (1981). Superoxide dismutase and oxygen toxicity. Clin. Respir. Physiol. 17, 85–89.
59. Teixeira, H.D, Schumacher, R.I. , Meneghini, R. (1998). Lower intracellular hydrogen peroxide levels in cells overexpressing CuZn-superoxide dismutase. Proc Natl Acad Sci 95, 7872–5.

60. Jaeschke, H. (1995). Mechanisms of oxidant stress-induced acute tissue injury. Proc. Soc. Exp. Biol. Med. 209: 104–111.
61. Akondi, B.R., Challa, S.R. , Akula, A. (2011). Protective Effects of Rutin and Naringin in Testicular Ischemia-Reperfusion Induced Oxidative Stress in Rats. J Reprod Infertil.12(3),209-214.
62. Nordberg, J. , Arner, E. S. (2001). Reactive oxygen species, antioxidants and the mammalian thioredoxin system. Free. Radic. Biol., 31, 1287-1312.
63. Bishnoi, M., Chopra, K. and Kulkarni, S.K. (2007). Protective effect of rutin, a polyphenolic flavonoid against haloperidol-induced orofacial dyskinesia and associated behavioural, biochemical and neurochemical changes. Fundam. Clin. Pharmacol. 21, 521–529.
64. Johansen, J.S., Harris, A.K., Rychly, D.J. et al., (2005). Oxidative stress and the use of antioxidants in diabetes: Linking basic science to clinical practice. Cardiovasc, Diabetol. 4: 5–7.
65. Takeuchi, K., Ueki, S. , Okabe, S. (1986). Importance of gastric motility in the pathogenesis of indomethacin-induced gastric lesions in rats. Dig. Dis. Sci., 31, 1114-1121.
66. Eşrefoğlu, M., Gül, M., Ateş, B. et al., (2006). Ultrastructural clues for the protective effect of ascorbic acid and N-acetylcysteine against oxidative damage on caerulein induced pancreatitis. Pancreatology, 6:477-85.
67. Nègre-Salvayre, A., Affany, A., Hariton, C. et al., (1991). Additional anti- lipoperoxidant activities of alpha tocopherol and ascorbic acid on membrane like systems are potentiated by rutin. Pharmacology, 42; (5):262-72.
68. 68. Annapurna, A., Reddy, C.S., Akondi, R.B. et al., (2009). Cardioprotective actions of two bioflavonoids, quercetin and rutin, in experimental myocardial infarction in both normal and streptozotocin-induced type I diabetic rats. J Pharm Pharmacol, 61(10),1365-74.
69. Bagchi, D., Mcginn, T. R., Ye, X. et al., (1999). Mechanism of gastroprotection by bismuth subsalicylate against chemically induced oxidative stress in cultured human gastric mucosal cells [esophageal, gastric, and duodenal disorders]. Dig Dis Sci. 44(12), 2419-2428.
70. Kalia, N., Bardhan, K.D., Reed, M.W. et al., (2000). Mast cell stabilization prevents ethanol-induced rat gastric mucosal injury: mechanisms of protection. J Gastroenterol, Hepatol. 15: 133-141.
71. Ohkura, Y., Furihata, T., Kawamata, H. et al., (2003). Evaluation of cell proliferation and apoptosis in Helicobacter pylori gastritis using an image analysis processor. Gastric Cancer 6; 49-54.
72. Kohda, K., Tanaka, K., Aiba, Y. et al., (1999). Role of apoptosis induced by Helicobacter pylori infection in the development of duodenal ulcer. Gut 44: 456-462.
73. Chattopadhyay, I., Nandi, B., Chatterjee, R. et al., (2004). Mechanism of antiulcer effect of Neem (Azadirachta indica) leaf extract: effect on H+-K+-ATPase, oxidative damage and apoptosis.Inflammopharmacology, 12, 153–176.
74. Fang, S.H., Rao, Y.K. , Tzeng, Y.M. (2008). Anti-oxidant and inflammatory mediator's growth inhibitory effects of compounds isolated from Phyllanthus urinaria. J Ethnopharmacol. 116: 333–340.
75. Shakeerabanu, M., Sujatha, K., Praveen Rajneesh, C. et al., (2011).The Defensive Effect of Quercetin on Indomethacin Induced Gastric Damage in Rats. Advances in Biological Research 5 (1): 64-70.
76. Kvietys, P.R., Twohig, B., Danzell, J et al., (1990). Ethanol-induced injury to the rat gastric mucosa. Role of neutrophil and xanthine oxidase derived radicals. Gastroenterology, 98: 909–920.
77. Zimmerman, B.J. , Granger, D. (1994). Oxygen free radicals and the gastrointestinal tract: role of ischemia-reperfusion injury. Hepatogastroenterology, 41, 337–342.
78. Fukumura, D., Kurose, I., Miura, S. et al., (1995). Oxidative stress in gastric mucosal injury: role of platelet-activating factor-activated granulocytes. J Gastroenterol; 30:565-571.
79. Vazquez-Ramirez, R., Olguin-Martinez, M., Kubli-Garfias, C. et al., (2006). Reversing gastric mucosal alterations during ethanol-induced chronic gastritis in rats by oral administration of Opuntia ficus-indica mucilage. World J Gastroenterol, 12, 4318–4324.
80. Pincemail, J., Deby, C., Thirion, A. et al., (1988). Human myeloperoxidase activity is inhibited in vitro by quercetin. Comparison with three related compounds. Experientia 44,450–3.
81. DIJKSTRA, G., MOSHAGE, H. , JANSEN, P.L. (2002). Blockade of NFkappaB activation and donation of nitric oxide: new treatment options in inflammatory bowel disease? Scand. J. Gastroenterol.,236 (Suppl), 37–41.
82. Dey, A. , Cederbaum, A.I. (2006). Alcohol and Oxidative Liver Injury. Hepatology, 43 (2): 563-574.
83. Konturek, P.C., Duda, A., Brzozowski, T. et al., (2000). Activation of genes for superoxide dismutase, interleukin-1β, tumor necrosis factor-α and intercellular adhesion molecule-1 during healing of ischemia – reperfusion gastric injury. Scand J Gastroenterol, 35;(5): 452-463.
84. Brzozowski T, Konturek PC, Konturek SJ, Sliwowski Z, Pajdo R, Drozdowicz D, et al., (2001).Classic NSAID and selective cyclooxygenase (COX)-1 and COX-2 inhibitors in healing of chronic gastric ulcers. Microsc Res Tech. 53:343–353. [PubMed]
85. Doyle, S.L., O'Neill, L.A.J. (2006). Toll-like receptors: from the discovery of NFκB tonew insights into transcriptional regulations in innate immunity. Biochem Pharmacol 72;(9):1102–1113.
86. Spranger, J., Kroke, A., Möhlig, M. et al., (2003). Inflammatory cytokines and the risk to develop type 2 diabetes: results of the prospective population-based European prospective investigation into cancer and nutrition (EPIC)-potsdam study. Diabetes 52(3).812–817.
87. 87. Tracey, K.J., Cerami, A. (1994).Tumor necrosis factor: a pleiotropic cytokine and therapeutic target. Annu Rev Med; 45: 491-503.
88. Robert, A. , Ruwart, M. (1982). Effect of prostaglandins on the digestive system. In: Prostaglandins, edited by Lee J. B., New York, Elsevier, pp. 113-176.
89. Ikari, A., Sakai, H., Tanaka, A. et al., (1999). Prostaglandin E2-activated housekeeping Cl- channels in the basolateral membrane of rat gastric parietal cells. Jpn J Physiol 49: 365-372.
90. Kargman, S., Charlesion, S., Cartwright, M. et al., (1993). Characterization of prostaglandin G/H synthase1 and 2 in rat, dog, monkey and human gastrointestinal tracts. Gastroenterology 111:445-454.
91. Lee, R.P., Subeq, Y.M., Lee, C.J. et al., (2012). Freshwater clam extract decreased hemorrhagic shock-induced liver injury by attenuating TNF-alpha production. Biol Res Nurs 14;(3):286–293.

© 2016; AIZEON Publishers; All Rights Reserved

This is an Open Access article distributed under the terms of the Creative Commons Attribution License which permits unrestricted use, distribution, and reproduction in any medium, provided the original work is properly cited.

*****